



PATIENT

Rusty Oneil

SPECIES

Canine

BREED

Chihuahua Mix

SEX

Male Neutered

AGE

11 years

WEIGHT

26.4lbs

INTERPRETED BY

Maggie Machen Lamy,
DVM, DACVIM
(Cardiology)

IMAGING PERFORMED BY

Loetitia Saint-Jacques,
LVT

HOSPITAL NAME

Mountain View Animal
Hospital

REFERRING VET

Dr. Mendoza

INVOICE

45877

DATE

11/20/25

PRESENTING CLINICAL SIGNS

History: Patient presented for general evaluation, on lab work noted elevation in LE, K, Ca and ALB, slight elevation in UPC concerning of liver vs adrenal vs neoplasia vs other disease and recommend perform AUS with possible sampling of liver or other findings during US. ECHO: Recheck echocardiogram, last performed on 9/19/24. Degenerative Valve Disease; ACVIM B1, moderate MR, normal LV dimension in diastole to borderline LVEH, normal LV systolic function, normal LA size, 9/8/22. Progressive, B2 with severe LAE, mild LVEH, normal systolic function, moderate MR, mild TR; 7/6/23. Improved/normal LV dimensions, improved LA dimensions, mild/mod LAE remains, mod MR, trivial TR, normal R heart size; 9/21/24. Linear structure (vs artifact) within RV. Current medications Pimobendan (Vetmedin) 5 mg tablets: Give 1/2 tablet(s) (2.5 mg) by mouth every 12 hours.

RADIOGRAPHIC FINDINGS *NOTE: Images submitted for supplemental information only.
Cardiomegaly. No obvious evidence of CHF.

ELECTROCARDIOGRAPHIC FINDINGS

A six lead ECG is available at 25mm/s; 10mm/mV. The average heart rate is 150bpm. The rhythm is sinus in origin, with a p for every QRS complex and vice versa. The P wave morphology is positive with a normal dimension. Normal PR. The QRS morphology is positive with normal dimension. MEA is normal. No ectopic beats, pauses or dysrhythmias observed. ECG diagnosis: Normal sinus rhythm.

ECHOCARDIOGRAM FINDINGS

2D, m-mode, color flow and doppler imaging is available. Diffuse thickening of mitral valve leaflets (anterior>posterior) with mild prolapse into the left atrial lumen. Moderate eccentric mitral regurgitation with moderate left atrial dilation. Normal MR velocity. Normal LV diameter with adequate myocardial function. The tricuspid valve appears mildly thickened, with no tricuspid regurgitation. Normal right atrial and ventricular diameter. The pulmonic and aortic valves are normal in morphology and mobility. Normal pulmonic and aortic outflow velocities. No aortic or pulmonic insufficiency. No pericardial or pleural effusion noted. No cardiac tumors observed.

CARDIAC CHART

CANINE CARDIAC PARAMETERS	MR VMAX (m/s)	TR VMAX (m/s)	LA/AO (Boon method)	LA/AO (Heart Base; Swe)	FS (%)	EF (%)	EPSS (cm)
NORMAL PARAMETER	4.5-5.5	<2.7	1.3	<1.6	28-40	40-100	<0.6
PATIENT	4.8	NA	1.8	1.7	47	80	NM
CANINE CARDIAC PARAMETERS	HR (BPM)	AV VMAX (m/s)	PV MAX (m/s)	BODY WEIGHT (kg)	LA 2D short axis Base view (cm)	LVIDd Avg; 2D and m-mode short axis (cm)	LVIDs Avg; 2D and m-mode short axis (cm)
NORMAL PARAMETER	50-100	0.7-1.7	0.7-1.6	BELOW	BELOW	BELOW	BELOW
PATIENT	158	1.6	1.2	12.0	2.5	2.8	1.3
*Normal chamber parameters expressed as a mean value (SD)				3	1.27 (5.3)	2.46 (2.46)	1.36 (5.5)
BODY WEIGHT DEPENDENT PARAMETERS				5	1.40 (4.5)	2.74 (5.2)	1.60 (4.7)
*Note: All measurements based upon multi-modal images and methods. An average value is reported.				10	1.50 (3.8)	3.27 (3.5)	2.06 (3.1)
				15	1.83 (2.0)	3.71 (2.4)	2.43 (2.1)
				20	2.02 (1.9)	4.14 (2.2)	2.80 (2.0)



PATIENT

Rusty Oneil

SPECIES

Canine

BREED

Chihuahua Mix

SEX

Male Neutered

AGE

11 years

WEIGHT

26.4lbs

INTERPRETED BY

Maggie Machen Lamy,
DVM, DACVIM
(Cardiology)

**IMAGING
PERFORMED BY**

Loetitia Saint-Jacques,
LVT

HOSPITAL NAME

Mountain View Animal
Hospital

REFERRING VET

Dr. Mendoza

INVOICE

45877

DATE

11/20/25

Adapted from June Boon, Veterinary Echocardiography, 1998	25	2.18 (2.4)	4.48 (2.9)	3.10 (2.5)
Rishniw M and Hollis NE, J Vet Intern Med 2000; 14:429-435	30	2.33 (3.3)	4.83 (3.9)	3.39 (3.4)
Hansson et al, Vet Rad and Ultrasound 2002	35	2.48 (4.3)	5.17 (5.0)	3.69 (4.5)
Bonagura et al. Echocardiography: principles of interpretation, Vet Clin North Am 15:1177, 1995	40	2.62 (5.2)	5.48 (6.1)	3.96 (5.4)
	50	2.88 (7.1)	6.07 (8.3)	4.46 (7.4)

INTERPRETATION OF THE FINDINGS & FURTHER RECOMMENDATIONS

Chronic degenerative valve disease causing moderate mitral regurgitation persists. Moderate left atrial enlargement and a normal LV indicates there is relatively low risk for imminent complication. No additional issues have developed, and the ECG is normal with a normal sinus rhythm.

Given these findings, reasonable to continue Pimobendan going forward. Assessment of progression in the future will help predict long term outcome; however, prognosis is guarded at this stage (B2). Fifty percent of stage B2 patients typically develop CHF within 2-2.5 years of diagnosis. The median time to development of CHF in B2 cases treated with pimobendan is 3.5 years.

Omega fatty acid supplementation and mild salt restriction may also be of some long-term benefit. Monitor for development of a progressive cough, labored breathing, exercise intolerance or collapse episodes.

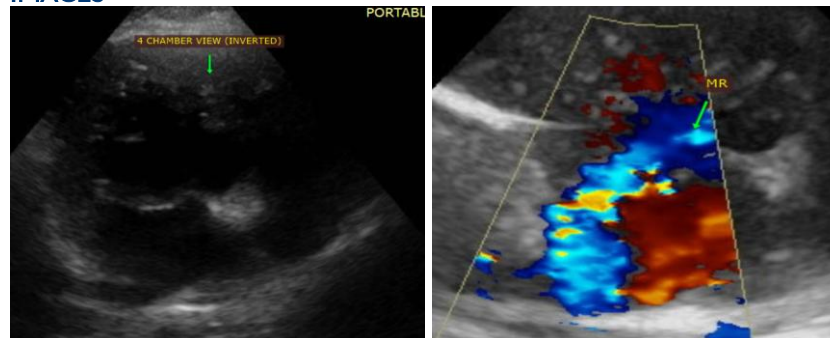
Anesthetic risk is considered mildly elevated. Cardiac protective drug choices (opioid/benzodiazepine premedication, Propofol or alfaxalone induction, iso or sevo gas) are recommended. Monitor for arrhythmias, hypotension, and hypoxia both intra and post-operatively and intervene as necessary. Judicious IV fluid rates are recommended to avoid fluid overload. Avoid heart rate stimulating drugs such as atropine unless clinically indicated.

PLAN

Baseline BP recommended. Continue Pimobendan 0.25-0.3mg/kg PO q12h.

Recommend monitor for progression with a recheck echocardiogram in 6 months, sooner if any development of clinical signs.

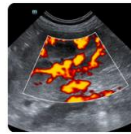
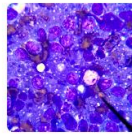
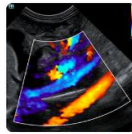
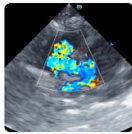
IMAGES



Imaging
performed by



Mountain View Animal Hospital, Inc.
pawsonography@gmail.com
530-786-8340



Clinical Sonography & Telectylogy
Educational Teleconsultation Services™

SonoPath

FOSTERING THE ART OF VETERINARY MEDICINE™

SonoPath.com info@sonopath.com 1.800.838.4268

PATIENT

Rusty Oneil

SPECIES

Canine

BREED

Chihuahua Mix

SEX

Male Neutered

AGE

11 years

WEIGHT

26.4lbs

INTERPRETED BY

Maggie Machen Lamy,
DVM, DACVIM
(Cardiology)

**IMAGING
PERFORMED BY**

Loetitia Saint-Jacques,
LVT

HOSPITAL NAME

Mountain View Animal
Hospital

REFERRING VET

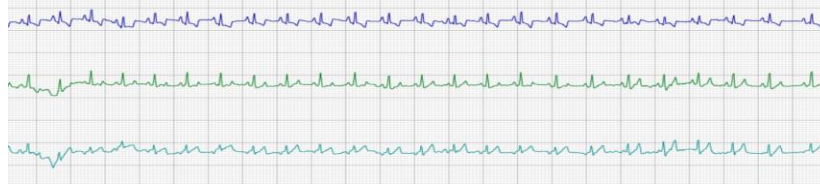Dr. Mendoza

INVOICE

45877

DATE

11/20/25



The information and recommendations provided are based on the images presented by the referring veterinarian. No evaluation can be communicated regarding pathology that was not visible in the image/video clips provided.

Thank you for this referral. This report was generated using transcription software, and minor dictation errors may be present. If the clinical or image interpretation does not parallel your findings or if I can be of any further assistance, please contact me.

Maggie Machen Lamy, DVM
Diplomate of the American College of Veterinary Internal Medicine (Cardiology)
info@sonopath.com